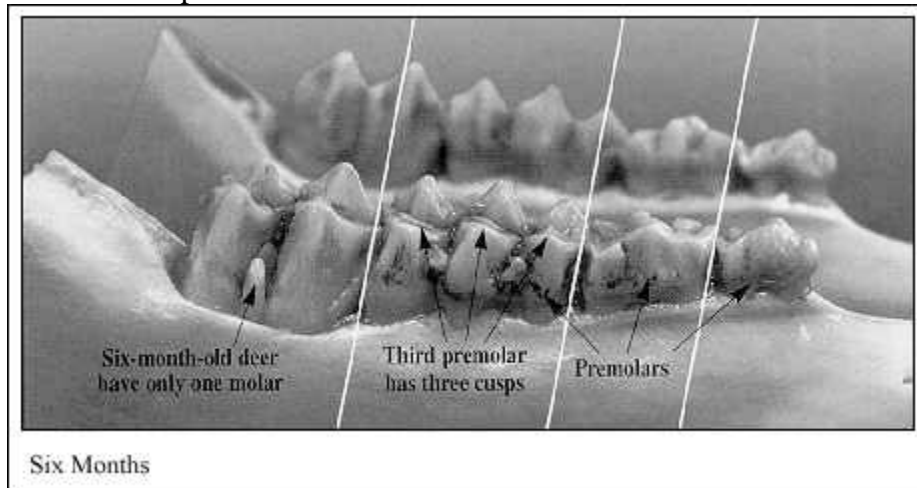


While it is possible to determine whether a deer is a fawn by looking at its incisors or front teeth, it is the cheek teeth, specifically those of the lower jaw, that harbor the most reliable clues.

To get a good look at the cheek teeth (premolars and molars), you need to cut back the lip and cheek skin. If you plan to have the head mounted, let your taxidermist skin out the head and remove the jaw for you.

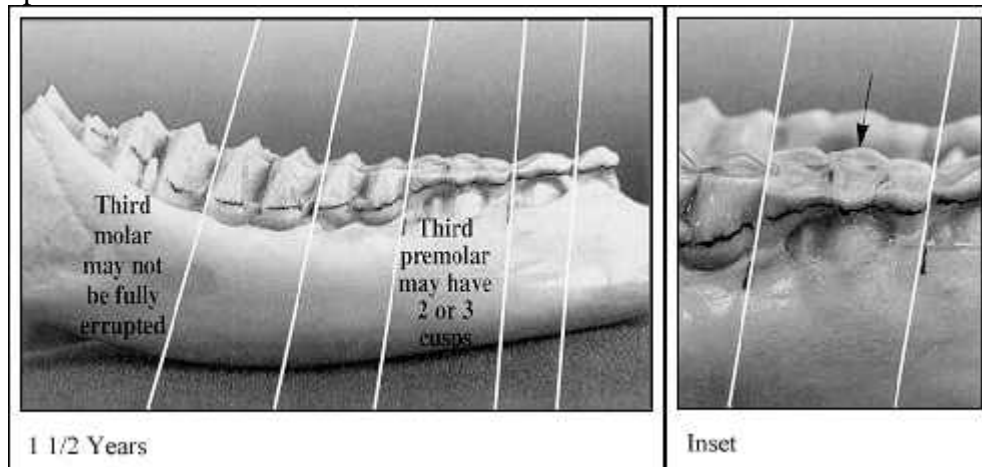
Six Months:

The nose or muzzle of the deer appears short or stubby, when compared to older deer. The central two incisors may still be erupting. Incisors may appear twisted as they emerge through the gum. Generally, there are only four cheek teeth showing. The third premolar has three cusps.



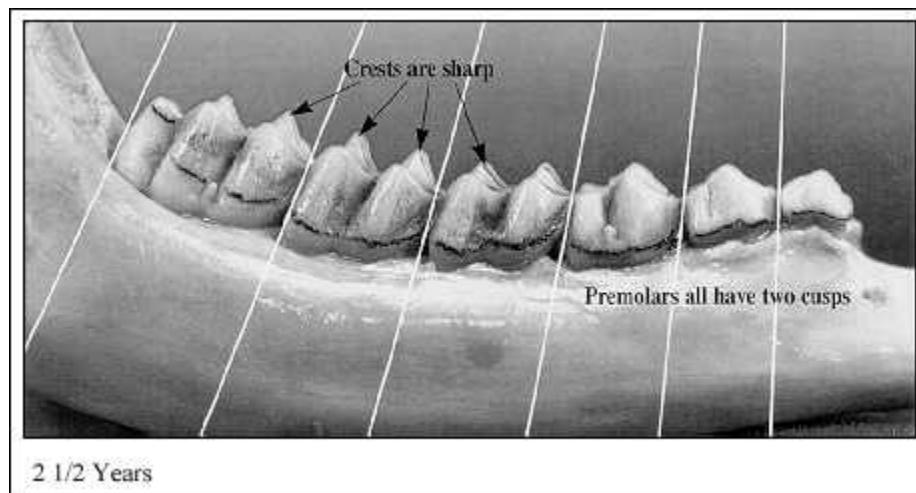
1-1/2; Years:

All permanent front teeth are in. Six cheek teeth are visible in the lower jaw. The third premolar may still have three cusps, or the permanent third premolar may now be in (two cusps). Third molar may still be erupting through the gum. Lingual crest of molars have sharp points. **Inset:** Extremely worn third premolar may fool people into thinking deer is older. Actually, this tooth is lost after 1-1/2; years and replaced with a permanent two-cusped premolar.



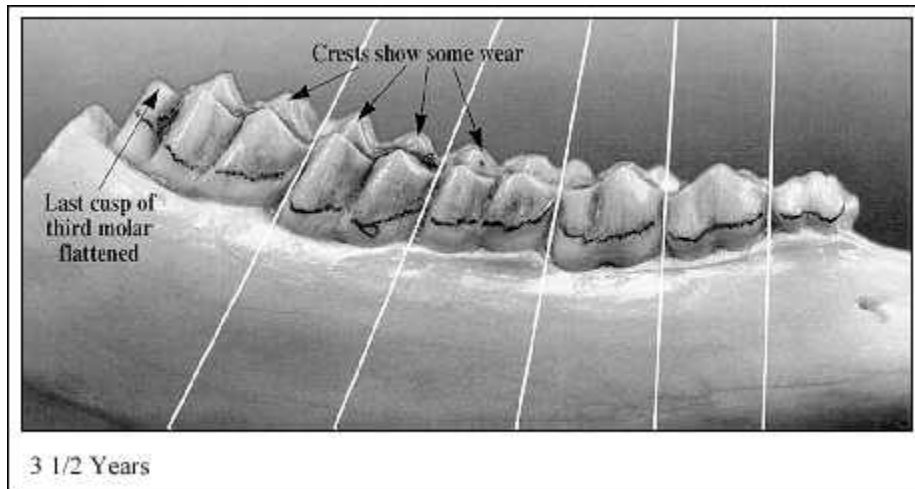
2-1/2; Years:

All permanent premolars and molars are in place. Look closely at the fourth cheek tooth (first molar). The cusps are sharp and show little or no wear; enamel (white portion) of the lingual crest shows well above the dentine (brown portion). The enamel portion of the cusp is wider than the dentine. Some wear on third cusp of sixth cheek tooth (third molar).



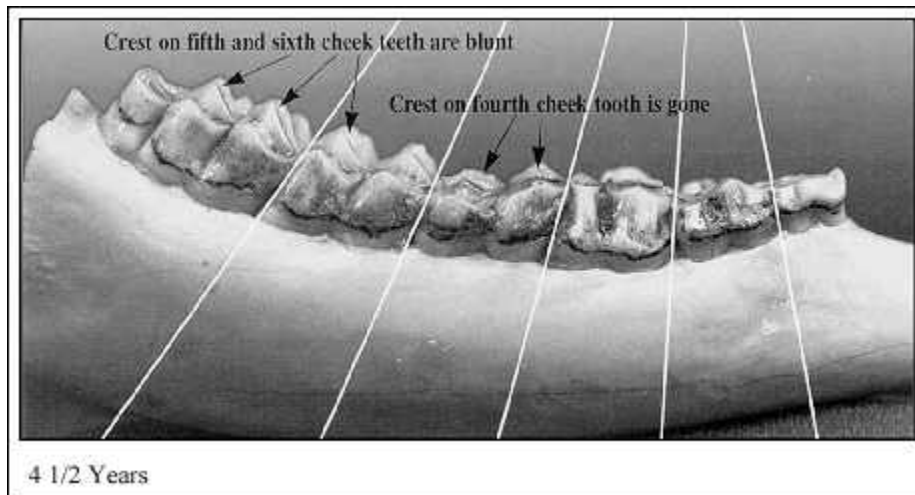
3-1/2; Years:

Lingual crests of cheek teeth show some wear and cusps are starting to become blunt. Dentine now thicker than enamel on cusp of fourth cheek tooth (first molar). Dentine of fifth cheek tooth (second molar) usually not as wide as enamel. Last cusp of sixth cheek tooth is flattened.



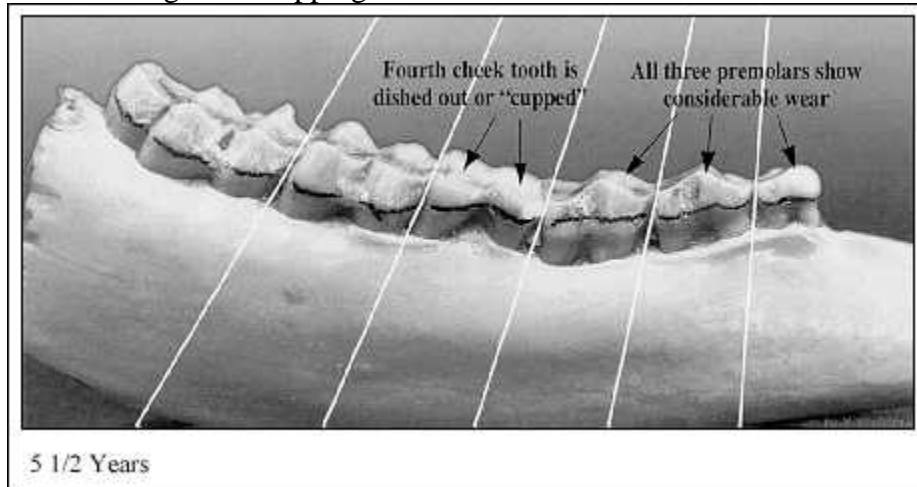
4-1/2; Years:

Lingual crest of fourth cheek tooth (first molar) is gone. Crest of cusps on fifth and sixth cheek teeth (second and third molar) are blunt. Dentine of fourth cheek tooth now twice as wide as enamel. Dentine of fifth cheek tooth wider than enamel.



5-1/2; Years and Older:

In most hunted deer populations, less than two percent of the animals are more than five years of age. Accurately aging these deer by tooth wear is usually more of a guessing game than a science. In general, deer close to 5-1/2; years of age will show considerable wear on the premolars, and the first cusp of the fourth cheek tooth (first molar) will be dished out or show signs of "cupping."



9-1/2; Years:

By 9-1/2; years, all cheek teeth are cupped and worn nearly to the gum line.

